



## REVIEW

# Mammary ductoscopy: current status and future prospects

Kefah Mokbel<sup>a,\*</sup>, Pedro F. Escobar<sup>b</sup>, Tadaharu Matsunaga<sup>c</sup>

<sup>a</sup>St George's Hospital, Blackshaw Road, London SW17 0QT, UK

<sup>b</sup>The Cleveland Clinic Foundation, USA

<sup>c</sup>Minami Aoyama Breastopia Clinic, Tokyo, Japan

Accepted for publication 8 October 2004

## KEYWORDS

Mammary ductoscopy;  
 Images;  
 Breast cancer;  
 Nipple discharge

**Abstract** *Background.* Mammary ductoscopy (MD) allows direct visualisation of the mammary ducts using sub-millimetre fiberoptic microendoscopes inserted through the ductal opening onto the nipple surface. The sharp clear magnified images are viewed on a video monitor. Such scopes have working channels that allow irrigation and ductal lavage for cytological analysis. MD can be performed under local anaesthesia in the office setting. This article reviews the evolving role of MD in the diagnosis and treatment of intraductal breast disease.

*Methods.* A literature search was carried out from Pubmed for indexed articles published over the last 30 years using the keywords 'mammary ductoscopy' and 'breast ductoscopy'.

*Results.* The search yielded 27 indexed published articles and reports. Important major reports and studies were reviewed, screened and tracked for other relevant publications. The most important articles were analysed and discussed. The review also includes our published and unpublished original work in the field of MD.

*Conclusions.* MD is a useful diagnostic adjunct in patients with pathological nipple discharge (PND). Furthermore, it can reduce the number and extent of duct excision operations for PND. However, its potential use in the early detection of breast cancer, guiding breast conserving surgery (BCS) for cancer, therapeutic ablation of intraductal disease, and guiding risk-reducing strategies among high risk women requires further research and evaluation. Future developments include the development of a biopsy kit, combining MD with molecular diagnostic markers and real-time optical biopsy system for the diagnosis of pre-malignant and early malignant disease and radiofrequency for curative ablation of intraductal lesions.

© 2004 Published by Elsevier Ltd.

## Introduction

The normal female adult breast is composed of two separate functional parts. One part is concerned with milk production and is known as the epithelial component.

\* Corresponding author. Tel.: +44 207 908 2040; fax: +44 207 908 2275.

E-mail address: kefahmokbel@hotmail.com (K. Mokbel).

113 The second part consists of all the other tissues  
114 that make up and support the breast including fat,  
115 fascia (connective tissue), vessels and muscle.

116 In the papilla of the nipple there is a parallel  
117 bundle of 11-48 central ducts (median 27, inter-  
118 quartile range 21-30)<sup>1,2</sup> although not all of them  
119 necessarily open onto the surface of the nipple. The  
120 number varies with disease and different stages of  
121 development and is increased at puberty, in  
122 pregnancy and lactation and reduced after the  
123 menopause and due to disease. Each of these  
124 segmental (main) ducts drains milk from different  
125 segments of the breast. Each segmental duct,  
126 branches into sub segmental first, second, third,  
127 fourth, fifth and sixth branches, finally forming the  
128 terminal duct-lobular unit (TDLU) which are also  
129 formed from lower-order branches. This TDLU is  
130 comprised of the extralobular terminal ducts,  
131 intralobular terminal ducts and the ductules. The  
132 intralobular terminal duct and the ductules then  
133 constitute a lobule. Studies have shown that normal  
134 mammary epithelium anatomically located in the  
135 TDLU is biologically associated with malignant  
136 change.<sup>1-3</sup> Going et al. demonstrated that in an  
137 autopsy breast, the largest duct system drained 23%  
138 of breast volume; half of the breast was drained by  
139 three ducts and 75% by the largest six central  
140 ducts.<sup>1</sup> The authors also described a 3D digital  
141 model of all collecting ducts in a mastectomy nipple  
142 using 68 100 microm serial sections. This revealed  
143 three distinct nipple duct populations. Seven ducts  
144 maintained a wide lumen up to the skin surface  
145 (population A); 20 ducts tapered to a minute lumen  
146 at the apex of the nipple within 1 mm from the skin  
147 surface (population B); and a minor duct population  
148 (seven ducts) arose at the base of the papilla  
149 (population C).<sup>1</sup> The authors observed no significant  
150 communications between the ducts. This important  
151 study suggests that only the first population of  
152 ducts (population A), which drained 75% of the  
153 breast volume, is accessible to MD. Further,  
154 research is required to establish whether anasto-  
155 moses exist between the various ducts and how  
156 frequently neoplasia affects the different duct  
157 populations. Understanding this anatomical  
158 arrangement of the mammary ducts is important  
159 in the context of MD.

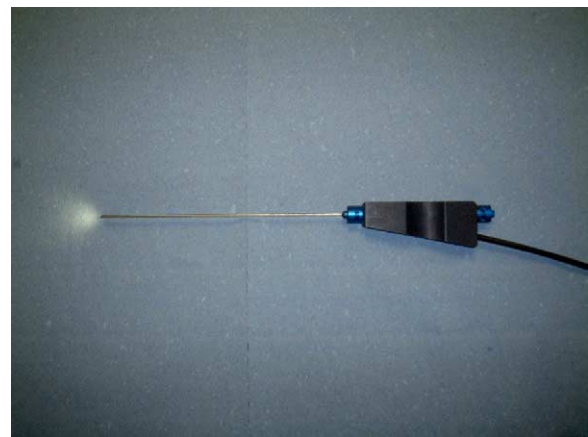
160 It is thought that 85% of pre-malignant and  
161 malignant breast lesions originate in the epithelial  
162 lining of the mammary ducts or lobules.<sup>1-3</sup> Yet until  
163 recently, we have not had direct access to this area  
164 other than removing tissue by core biopsy or fine  
165 needle aspiration. Furthermore, conventional ima-  
166 ging modalities such as mammography and ultra-  
167 sonography are associated with significant false  
168 negative results.<sup>4</sup> These observations made it

169 logical to explore the role of endoscopic visualisa-  
170 tion of the mammary duct system.

171 MD has been evolving over the last 15 years.<sup>5-10</sup>  
172 The earlier attempts were constrained by limited  
173 optics, large calibre scopes and lack of working  
174 channels for insufflation and biopsy under direct  
175 visualisation.<sup>5-8</sup> Furthermore, the images gener-  
176 ated by the earlier scopes were too small and  
177 imprecise for accurate clinical judgement.

178 Recent technological advances in endoscopic  
179 techniques, however, have overcome many of  
180 these obstacles. The current generation of micro-  
181 endoscopes (rigid or flexible) use excellent fibreop-  
182 tics and measure between 0.9 and 1.2 mm in  
183 external diameter.<sup>5,10</sup> Such microendoscopes  
184 allow surgeons to magnify breast tissue up to 60  
185 times the normal size and pinpoint small lesions and  
186 can be gradually moved into peripheral sites. They  
187 also yield large, clear and sharp video images of the  
188 mammary duct system and provide working chan-  
189 nels for insufflation, extraction of tissue for  
190 diagnosis and possible therapeutic intervention  
191 (Fig. 1).

192 The endoscope is inserted through the ductal  
193 opening on the nipple surface after dilating the duct  
194 with a suitable probe (e.g. Bowman's lacrimal  
195 dilators). Saline solution is injected into the duct  
196 through the working channel in order to widen it  
197 and facilitate the passage of the endoscope for  
198 clear visualisation of the intraductal space. The  
199 optical viewing and endoscopic system magnifies  
200 breast tissue up to 60 times its actual size and  
201 allows the identification of breast lesions up to  
202 1/100th the size of those detected with conven-  
203 tional mammography and magnetic resonance  
204 imaging (MRI). The procedure can be performed  
205 under local anaesthesia (topical local anaesthetic  
206  
207  
208  
209  
210  
211  
212  
213  
214  
215  
216  
217  
218  
219  
220  
221  
222



223 **Figure 1** A breast ductoscope with a 1 mm external  
224 diameter and a 0.45 mm working channel.

cream plus intradermal local anaesthetic injection at the areolar margin) in the office setting and has no significant complications.<sup>5,10</sup>

## Current indications

An important potential clinical application of MD is pathological nipple discharge (PND), where current imaging techniques and cytological examination of the discharge fluid usually fail to demonstrate the underlying pathology. PND is a relatively common symptom accounting for approximately 5% of all women attending symptomatic breast clinics.<sup>11</sup> Papilloma is the commonest pathological finding in women with PND accounting for 40-70% of cases<sup>11,12</sup> followed by adenomatous or papillary epithelial proliferations (14%). However, the incidence of malignancy (invasive or in situ) as a cause of PND varies between 1 and 23% depending upon the series studied.<sup>11</sup> The only reliable way to both establish the diagnosis and control the discharge is ductal excision, the success of which is dependant on identifying the correct origin of the discharge. When a specific duct cannot be identified then blind excision of the retroareolar ductal system is usually performed.

MD offers the advantages of accurate localisation of pathology, ductal lavage under direct visualisation, and intraoperative guidance especially for lesions deep within the ductal system.<sup>12</sup> In addition to visualising intraductal lesions, cytological analysis of endoscopically retrieved ductal lavage has been recently reported to be more accurate than simple discharge cytology (5,9,10). In a cohort of 415 patients with PND, ductoscopy was successful in visualising an intraductal lesion in 166 patients (40%). In these cases, ductal lavage following ductoscopy increased the yield of cytologically interpretable ductal epithelial cells 100-fold compared to discharge fluid alone.<sup>10</sup> The authors also reported that of the 11 cases of DCIS that were initially detected with a combination of MD and ductal lavage cytology, six were completely negative on clinical examination and mammography.

Dietz et al. reported that duct cannulation was achieved in 105 (88%) of 119 patients with PND and ductoscopy directed duct excision could be performed in 104 (87%) of 119 cases. These authors also found that MD was more accurate than pre-operative ductography (90 vs 76%) in localising the relevant pathology. The pathological diagnoses were malignancy in five patients, papilloma in 84 cases, and hyperplasia in 16. In 22 patients, ductoscopy visualised multiple lesions or

abnormalities beyond 4 cm. Such lesions would have been missed by blind duct excision.

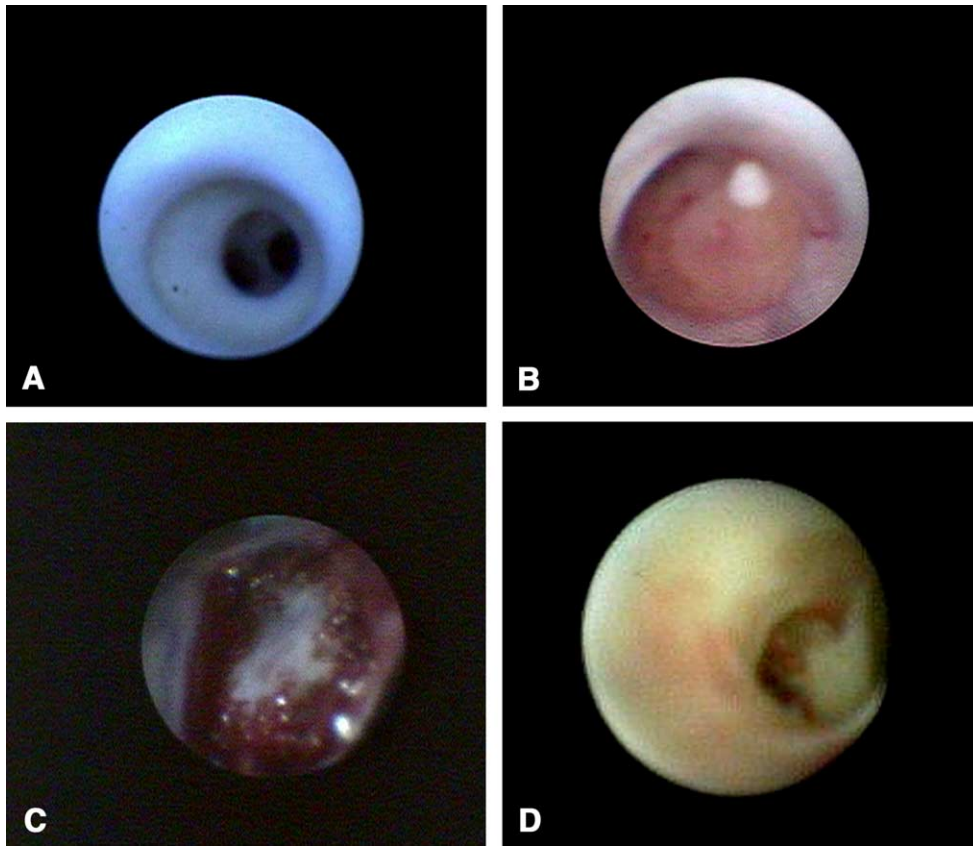
Okazaki et al.<sup>7</sup> performed MD in 46 patients with PND using two kinds of silicafiber scopes with outer diameters of 0.80 and 0.45 mm. The authors observed that the internal surface of a normal duct was lustrous and smooth, whereas cancer arising from the epithelial lining of the mammary ducts appeared white and was slightly elevated, forming a bridging structure. Intraductal papillomas formed intraductal solid nodules, being yellow in most cases and red at the site of haemorrhage (Fig. 2).

Our group performed MD in 315 patients with PND.<sup>13</sup> This study evaluated the use of MD in not only diagnosing intraductal lesions such as DCIS and papillomas but also in the treatment of intraductal papillomas. In this study carcinoma was recognised by MD in 38 (81%) of 47 cases and intraductal papilloma lesions in 115 (96.6%) of 119 cases. The shape of the lesions seen was classified as hemispheric, papillary and flat protrusion type. The hemispheric and papillary shapes were most common in cases of intraductal papilloma and the flat protrusion type was most common in cases of carcinoma. We performed intraductal biopsies of 69 papillomas and obtained adequate tissue material for histological diagnosis in 52 (75.4%) cases. Furthermore, we observed therapeutic effectiveness in 82.6% of cases biopsied during follow-up.

Dooley et al.<sup>14</sup> used a 0.9 mm microendoscope in 27 patients who were undergoing nipple exploration for spontaneous haemoccult positive PND. In 26 (96%) of 27 patients, the endoscope was successfully introduced into the lactiferous sinus, and the proximal mammary ducts were successfully visualised. A lesion accounting for the bleeding was seen in all 26 patients with 70% having multiple intraluminal defects. DCIS was identified in two cases and in both cases there was a more proximal papilloma in the same ductal system. In three other cases both papilloma and atypical hyperplasia were present. Although most lesions are located within 3 cm from the nipple, some lesions identified extended up to 7.5 cm deep to the nipple.<sup>14</sup> The deepest endoscopically identified lesion was carcinoma in a patient with normal mammography and ultrasound.

Simple light transillumination through the skin during MD can be used to guide duct excision. We have recently described a new technique involving ductoscopy and the use of a blue dye to perform microdochectomy.<sup>15</sup> MD can also potentially reduce the need to perform duct excision in patients with

281  
282  
283  
284  
285  
286  
287  
288  
289  
290  
291  
292  
293  
294  
295  
296  
297  
298  
299  
300  
301  
302  
303  
304  
305  
306  
307  
308  
309  
310  
311  
312  
313  
314  
315  
316  
317  
318  
319  
320  
321  
322  
323  
324  
325  
326  
327  
328  
329  
330  
331  
332  
333  
334  
335  
336



**Figure 2** Mammary ductoscopy images. (A) Normal mammary ducts. (B) An intraductal papilloma. (C, D) DCIS.

PND due to benign disease thus resulting in cost savings.

### MD and breast cancer

Since 85% or more of breast cancers originate in the epithelial lining of mammary ducts from morphologically identifiable precursor lesions, therefore MD can potentially detect breast cancer several years before detection<sup>1-3</sup> by mammography. Shen et al. reported that of the 11 cases of DCIS that were initially detected with a combination of MD and ductal lavage cytology in women with PND, six (54%) were completely negative on mammography and physical examination.<sup>10</sup>

However, this potential role of MD in the early detection of breast cancer will be enhanced by the development of a biopsy kit that allows adequate microbiopsy for histological diagnosis.

The intraductal approach to breast cancer has been recently invigorated with series of papers exploring ductal based screening through nipple aspiration, ductal lavage and more recently ductoscopy.<sup>16</sup> Ductal lavage is a minimally invasive procedure, which can detect cytological atypia via

retrieval of breast ductal fluid. Despite the lack of reliable evidence supporting the role of ductal lavage, it is currently being used in several centres to guide risk-reducing strategies in high risk women.<sup>17</sup> When frankly malignant cells are present in the lavage fluid, the diagnosis can be confirmed with mammography, ultrasound and/or magnetic resonance imaging (MRI). If these investigations are negative for malignancy then ductal imaging (ductography and/or MD) can be performed. Hence, MD can complement mammary ductal lavage in breast cancer screening but has the advantage of direct visualisation of intraductal pathology and obtaining a higher epithelial cell yield from the surface of the lesion. Although MD seems to be promising in the early detection of breast cancer<sup>10,18,19</sup> and defining the presence and extent of proliferative disease in high risk patients and could potentially be a complementary screening procedure, there is a clear need to design prospective clinical trials evaluating its potential role in breast cancer screening and guiding risk-reducing strategies.

Dooley et al.<sup>19</sup> used a flexible fiberoptic microendoscope in 55 women who were going to undergo partial mastectomy after having been diagnosed with ductal hyperplasia, DCIS, or invasive breast

cancer identified by conventional diagnostic tests. The index quadrant was massaged to express nipple discharge prior to endoscopy. The procedure was successful in 47 (85.5%) of 55 patients and the target lesion was identified by MD in 41 (75%) of 47 cases. Furthermore, the authors found more extensive disease than predicted by pre-operative assessment in 21 (45%) of 47 cases and these patients required a wider breast resection than previously anticipated. Randomised controlled trials are needed to validate such observations suggesting that MD can guide breast conserving surgery (BCS) and reduce the need for re-excision procedures, especially, in patients with DCIS.

### The limitations

At present, breast cancer is believed to originate within the TDLUs, through succession of events involving DCIS. Therefore, visual and/or cytological examination of these structures would permit identification of abnormal lesions before the development of invasive disease. Although MD provides useful information regarding the ductal system, the procedure has several limitations. MD usually examines 1-2 ducts per breast and leaves the remaining approximately 13-18 ducts that open at the nipple of each breast unexamined.<sup>20</sup> Although the main central ducts (median number=7) draining 75% of the breast volume are accessible to MD,<sup>1</sup> it is not currently known, however, whether these ducts are the commonest sites of neoplasia development.

MD permits direct visualisation of the lactiferous duct, lactiferous sinus, and the segmental duct and its main branches. However, its capability for direct observation of lesions in smaller calibre peripheral ducts and the TDLUs where the pre-malignant and malignant lesions often originate is limited by the outer diameter of the scope and the complex branching pattern of the mammary ducts thus limiting the sensitivity of the technique. Lumen occlusion by disease, scarring or sclerosis, false tract formation, and acute angulation of ductal branches are recognised causes of distal ductoscopy failure.<sup>5</sup> In addition, the ductal washings during MD retrieves only one third of the fluid originally infused. Therefore, there is a considerable fraction of fluid and cells that remain trapped, probably within the smaller, more distally located ducts. Furthermore, ductoscopic cytology frequently reveals atypia in cases of papilloma,<sup>21</sup> therefore, there is a need to develop a reliable biopsy technique that accurately establishes the

histological diagnosis. Badve et al.<sup>20</sup> examined 801 mastectomy specimens, and found that 14% of intraductal carcinoma did not have an in situ component. These findings were even lower than that reported in a study undertaken by the national surgical adjuvant breast and bowel project (NSABP), which examined almost 1000 mastectomies and found the absence of an in situ component in >30% of cases.<sup>22</sup> Whether the lack of a demonstrable in situ component is a result of it being overrun by the invasive process or due to its genuine absence is a matter of speculation. These observations raise the possibility that a significant percentage of patients (14-30%) undergoing mastectomy for breast cancer would not have an intraductal component and therefore MD would not be able to directly visualise malignancy. However, invasive malignancy may cause extrinsic duct compression that can be visualised by MD.<sup>21</sup>

### Future prospects

With greater improvements in the newer generation microendoscopes, it is possible to manoeuvre them into more peripheral sites. The development of a biopsy kit that allows adequate microbiopsies for histological diagnosis is likely to enhance the role MD in breast cancer screening in high-risk women and reduce the need for duct excision in patients with PND due to benign disease. Our group have recently described a reliable mammoscopically-guided intraductal biopsy technique, which also had a therapeutic benefit in 38 (82.6%) of 46 intraductal papillomas.<sup>13</sup> The intraductal biopsies were performed using a needle with a side hole passed through a sheath after removal of the mammoscope. Although the technique was effective, however it was not performed under direct visualisation. There is a clear need to develop a reliable biopsy technique (under direct visualisation) and this objective can be achieved by close cooperation between breast specialists and manufacturers.

There is growing evidence that mammary ductal lavage cytology using microcatheters is effective in identifying atypical and malignant cells in high risk women and thus in guiding risk-reducing strategies.<sup>23</sup> This has stimulated interest in exploring the potential role of MD in breast screening as a complementary technique to ductal lavage in patients with atypical or malignant cytology. Furthermore, it is likely to complement other non-invasive screening tests which measure electrical impedance or thermovascular changes related to angiogenesis on the surface of the breast,

especially, that these tests are thought to detect mammary carcinogenesis several years earlier than screening mammography.<sup>24</sup>

MD allows direct visualisation of occult ductal pathology and ductal lavage of abnormal areas. This technique can be combined with the use of molecular and genetic markers of malignancy.<sup>25,26</sup> The potential role of MD in the early detection of pre-malignant and malignant disease can be enhanced by combining it with real-time optical biopsy techniques.<sup>27</sup> Furthermore, the addition of radiofrequency could lead to curative endoscopic ablation of these lesions.<sup>28</sup> These potential applications underscore the need to develop reliable methodology to mark the ducts harboring pathology.

## References

- Wellings SR, Jensen HM, Marcum RG. An atlas of subgross pathology of the human breast with special reference to possible precancerous lesions. *J Natl Cancer Inst* 1975;**55**: 231-73.
- Going JJ, Moffat DF. Escaping from flatland: clinical and biological aspects of human mammary duct anatomy in three dimensions. *J Pathol* 2004;**203**:538-44.
- Sparks CA. Using ductoscopy to detect breast mass at an early stage. *AORN J* 2002;**76**:851-4.
- Brenner RJ. False-negative mammograms. Medical, legal and risk management implications. *Radiol Clin North Am* 2000;**38**:741-57.
- Mokbel K, Elkak AE. The evolving role of mammary ductoscopy. *Curr Med Res Opin* 2002;**18**:30-2.
- Makita M, Sakamota G, Akiyama F, et al. Duct endoscopy and endoscopic biopsy in the evaluation of nipple discharge. *Breast Cancer Res Treat* 1991;**18**:179-88.
- Okazaki A, Okazaki M, Asaishi K, et al. Fiberoptic ductoscopy of the breast: a new diagnostic procedure for nipple discharge. *Jpn J Clin Oncol* 1991;**21**:188-93.
- Berna JD, Gracia-Medina V, Kuni CC. Ductoscopy: a new technique for ductal exploration. *Eur J Radiol* 1991;**12**: 127-9.
- Okazaki A, Hirata K, Okazaki M, Svane G, Azavedo E. Nipple discharge disorders: current diagnostic management and the role of fiber-ductoscopy. *Eur Radiol* 1999;**9**:583-90 [Review].
- Shen KW, Wu J, Lu JS, et al. Fiberoptic ductoscopy for breast cancer patients with nipple discharge. *Surg Endosc* 2001;**15**: 1340-5.
- Paterok EM, Rosenthal H, Sabel M. Nipple discharge and abnormal galactogram. Results of a long-term study (1964-1990). *Eur J Obstet Gynaecol Reprod Biol* 1993;**50**:227-34.
- Dietz JR, Crowe JP, Grundfest S, Arrigan S, Kim JA. Directed duct excision by using mammary ductoscopy in patients with pathologic nipple discharge. *Surgery* 2002;**132**:582-7.
- Matsunaga T, Ohta D, Misaka T, Hosokawa K, Fujii M, Kaise H, et al. Mammary ductoscopy for diagnosis and treatment of intraductal lesions of the breast. *Breast Cancer* 2001;**8**(3): 213-21.
- Dooley WC. Routine operative breast endoscopy for bloody nipple discharge. *Ann Surg Oncol* 2002;**9**:920-3.
- Escobar PF, Baynes D, Crowe JP. Ductoscopy-assisted microdocheotomy. *Int J Fertil Womens Med* 2004 [in press].
- Dooley WC. Ductal lavage, nipple aspiration, and ductoscopy for breast cancer diagnosis. *Curr Oncol Rep* 2003;**5**:63-5.
- Hollingsworth AB, Singletary SE, Morrow M, et al. Current comprehensive assessment and management of women at increased risk for breast cancer. *Am J Surg* 2004;**187**: 349-62.
- Mokbel K, Perrira B, Khalifa K. Mammary ductoscopy in human mastectomy specimens: the feasibility and the limitations. *Eur J Cancer (supplement)* 2004;**2**:97 [Abstr 148].
- Dooley WC. Endoscopic visualization of breast tumours. *JAMA* 2000;**284**:1518.
- Badve S, Wiley E, Rodriguez N. Assessment of utility of ductal lavage and ductoscopy in breast cancer—a retrospective analysis of mastectomy specimens. *Mod Pathol* 2003;**16**: 206-9.
- Sauter ER, Ehya H, Schlatter L, MacGibbon B. Ductoscopic cytology to detect breast cancer. *Cancer J* 2004;**10**:33-41.
- Fisher ER, Gregorio RM, Fisher B, Redmond C, Vellios F, Sommers SC. The pathology of invasive breast cancer. A syllabus derived from findings of the national surgical adjuvant breast project (protocol no. 4). *Cancer* 1975;**36**: 1-85.
- Dooley WC, Ljung BM, Veronesi U, et al. Ductal lavage for detection of cellular atypia in women at high risk for breast cancer. *J Natl Cancer Inst* 2001;**93**:1624-32.
- Folkman J, Watson K, Ingber D, Hanathan D. Induction of angiogenesis during the transition from hyperplasia to neoplasia. *Nature* 1989;**339**:58-61.
- Evron E, Dooley WC, Umbricht CB, et al. Detection of breast cancer cells in ductal lavage fluid by methylation-specific PCR. *Lancet* 2001;**357**:1335-6.
- Mokbel K. Nipple endoscopy: focus on a new diagnostic tool. *Int J Fertil Womens Med* 2003;**48**:197-9.
- Bigio IJ, Bown SG, Briggs G, Kelley C, et al. Diagnosis of breast cancer using elastic-scattering spectroscopy: preliminary clinical results. *J Biomed Opt* 2000;**5**:221-8.
- Burak Jr WE, Agnese DM, Povoski SP. Radiofrequency ablation of invasive breast carcinoma followed by delayed surgical excision. *Cancer* 2003;**98**:1369-76.

617  
618  
619  
620  
621  
622  
623  
624  
625  
626  
627  
628  
629  
630  
631  
632  
633  
634  
635  
636  
637  
638  
639  
640  
641  
642  
643  
644  
645  
646  
647  
648  
649  
650  
651  
652  
653  
654  
655  
656  
657  
658  
659  
660  
661  
662  
663  
664  
665  
666  
667  
668  
669  
670  
671  
672